




# **Straight to the Point: Talking IUC**

Step-by-step guidance to addressing  
concerns with intrauterine contraception



# The INTRA group

- **INTRA group:** Intrauterine coNtraception: **T**ranslating **R**esearch into **A**ction
  - A panel of independent physicians with expert interest in intrauterine contraception
  - **Purpose:** To encourage more widespread use of IUC methods in a broad range of women through medical education

## Group members



Dr Katty Ardaens  
France



Professor Kai Bühling  
Germany



Dr Brian Hauck  
Canada



Dr Josefina Lira  
Mexico



Dr Pamela Lotke  
USA



Dr Tina Peers  
UK



Professor Nikki Zite  
USA

- Formation of the INTRA group and its ongoing work is supported by Bayer Pharma



- Despite the availability of an extensive range of contraceptive options, a high number of pregnancies are unplanned<sup>1</sup>
- IUC is a highly effective method of contraception<sup>2,3</sup>
- In 95% of women it can be placed easily and successfully,<sup>4-7</sup> and risk of complications is low<sup>7,8</sup>
- However, concerns around placement and potential complications prevent some HCPs from recommending IUC<sup>9</sup>
- The INTRA group provides step-by-step guidance to address these concerns
- For help in addressing your particular concern, click on the appropriate icon

**Difficult placement**


**No threads visible**

**Bleeding**

**Pain**

**Infection**

**Perforation**



# Difficult placement

Perforation at time of insertion (with sound)

Return for placement with ultrasound (in 2-3 weeks if patient still motivated to use IUC)

Failed attempt

Severe pain

Counsel and reassure patient extensively for another attempt at placement

**Pain**

## Ultrasound guidance

- Ensure no creation of false passage
- Metal sound easy to see on abdominal ultrasound in non-obese women
- A low position in the uterus i.e. not at the fundus, is not generally a concern (as long it is not in the cervical canal) but back-up contraception and a re-scan in 2-4 weeks to check if migrated into optimal position may provide reassurance

- Misoprostol
- Place during menses

## Mechanical help

- Os finder or cytobrush
- Sterilized or one way Hegar (or Pipelle) to identify path of endocervical canal
- Adequate traction with tenaculum
- Repositioning of tenaculum (to get round 'kinks' or 'lip' in cervical canal)
- Small 5 mm Denniston dilator to achieve greater dilation

Correlate bimanual exam with uterus sounding



## Additional information

CLOSE

## Ease of insertion: myth versus reality

- **Myth:** It is very difficult/impossible to insert IUC in nulliparous women
- **Reality:** In the vast majority of women, IUC is inserted with ease regardless of parity<sup>4-6</sup>

Reference	Country	Sample size and composition	% of LNG-IUS placements rated as 'easy'	% of successful LNG-IUS placements
Marions <i>et al</i> , 2011 <sup>4</sup>	Sweden	224 nulliparous women	72%	97.4%
Suhonen <i>et al</i> , 2004 <sup>5</sup>	Finland and Sweden	94 nulliparous women	85%	97.9%
Bahamondes <i>et al</i> , 2011 <sup>6</sup>	Brazil	159 nulligravid women	81%	99.4%

into optimal position may provide reassurance

## References

**Disclaimer:** Please note that these statements and practical recommendations are based on the INTRA group's expert opinion, and therefore may not be in line with the labelling information of intrauterine contraceptive devices in your country

# No threads visible

- Use cytobrush to retrieve threads
- Palpate

Unable to confirm IUC with cytobrush

No immediate access to ultrasound

Immediate access to ultrasound

Check pregnancy test

Able to confirm IUC

Low position in uterus

Position at the fundus

Remove if embedded in myometrium

Reassure

Negative test

Positive test

Unable to confirm IUC with cytobrush or ultrasound and negative pregnancy test

Schedule ultrasound  
Counsel on other contraceptive options and consider EC if indicated

Abdominal/pelvic X-ray (or schedule and counsel on other contraceptive options and consider EC if indicated)

Unable to confirm IUC

- If Cu-IUD:
- Counsel patient on pregnancy risk if Cu-IUD does not move into position
  - Check position at 3 months if needed

- If LNG-IUS:
- Reassure patient that the low position will not impact on efficacy<sup>7</sup>

IUC in abdomen

No IUC seen

Recommend surgical management

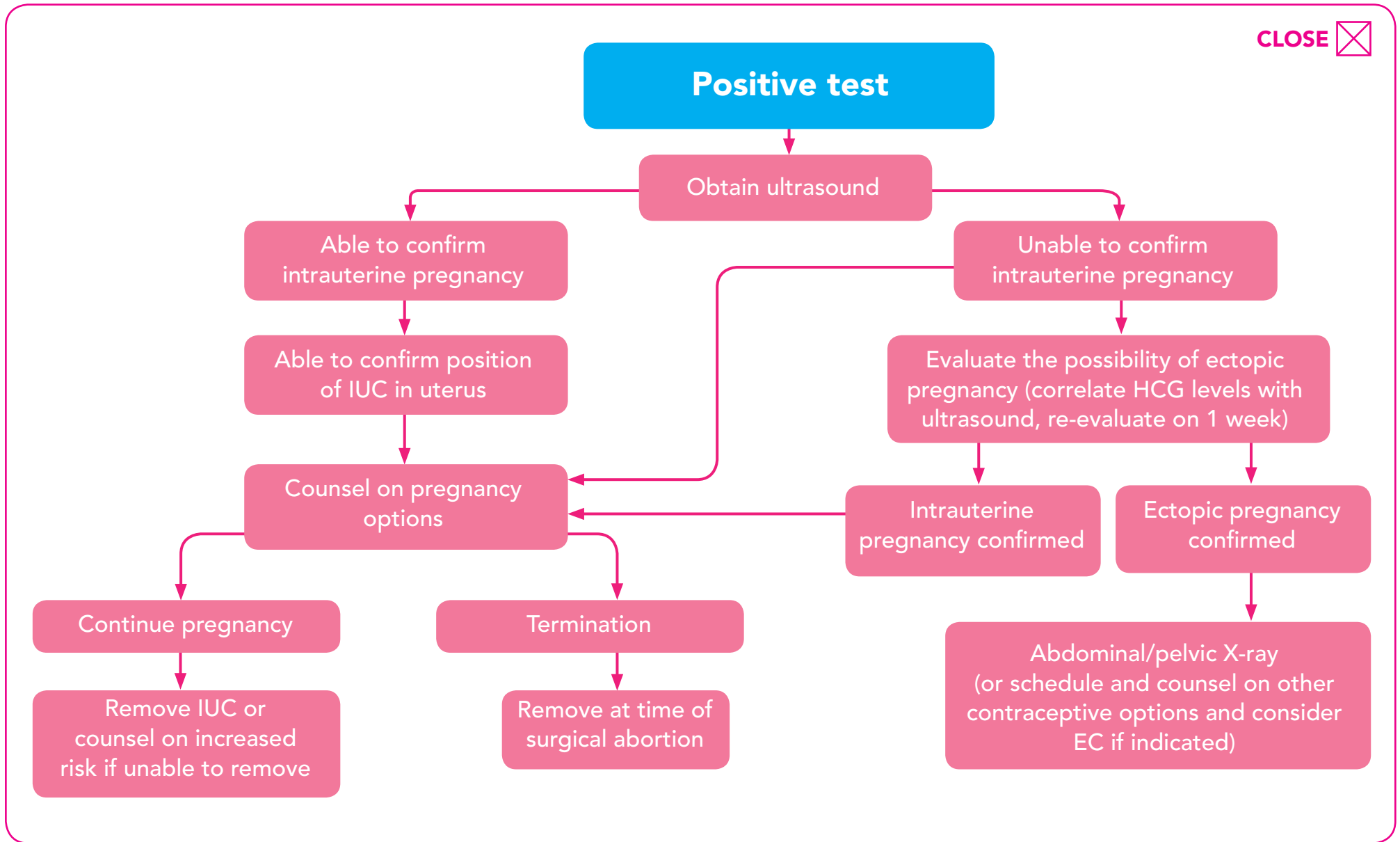
Assume expulsion

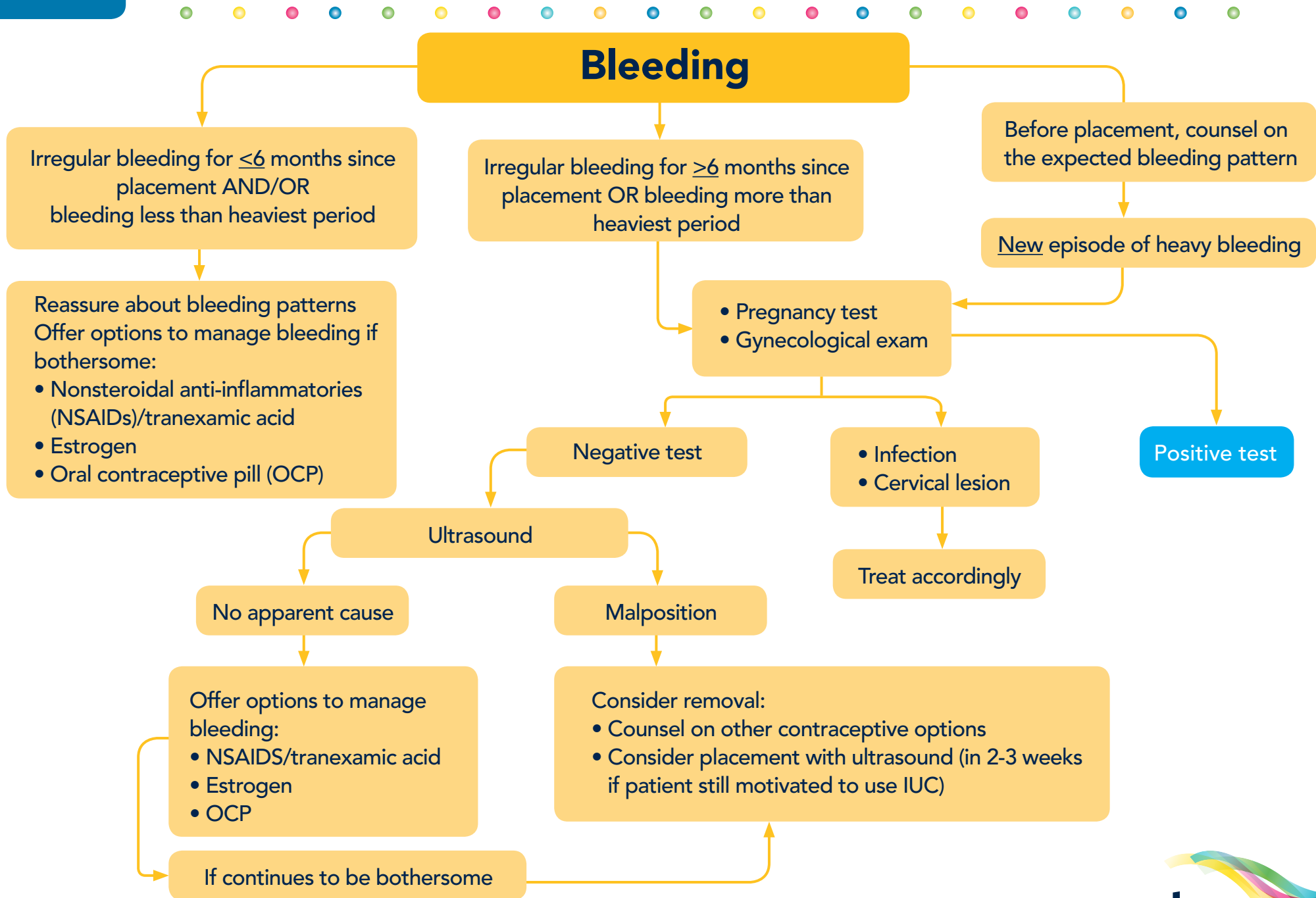
- If patient requests IUC removal:
- Use cytobrush, palpation, IUS hook, and packing forceps

Contraceptive counselling

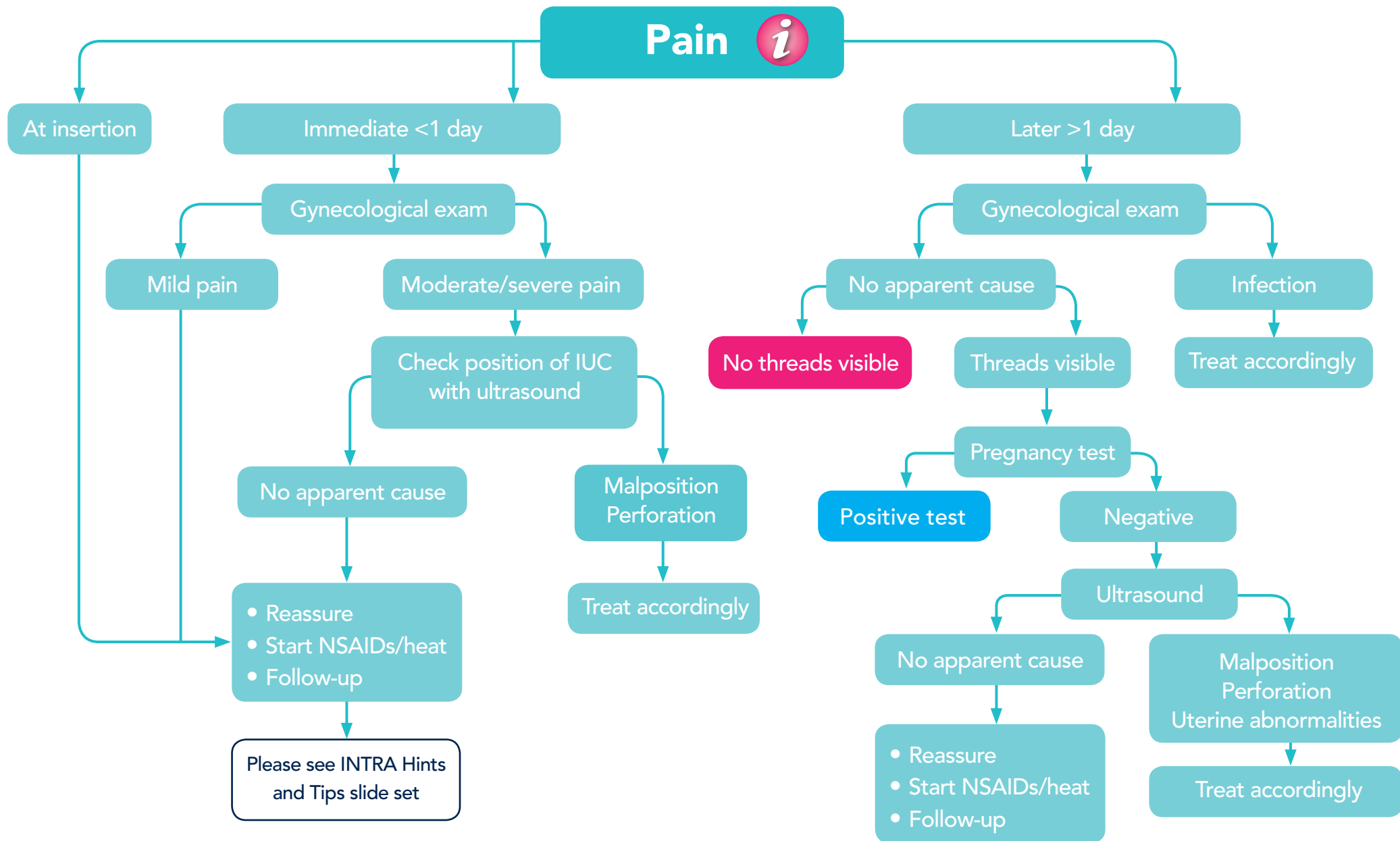
## References

**Disclaimer:** Please note that these statements and practical recommendations are based on the INTRA group's expert opinion, and therefore may not be in line with the labelling information of intrauterine contraceptive devices in your country



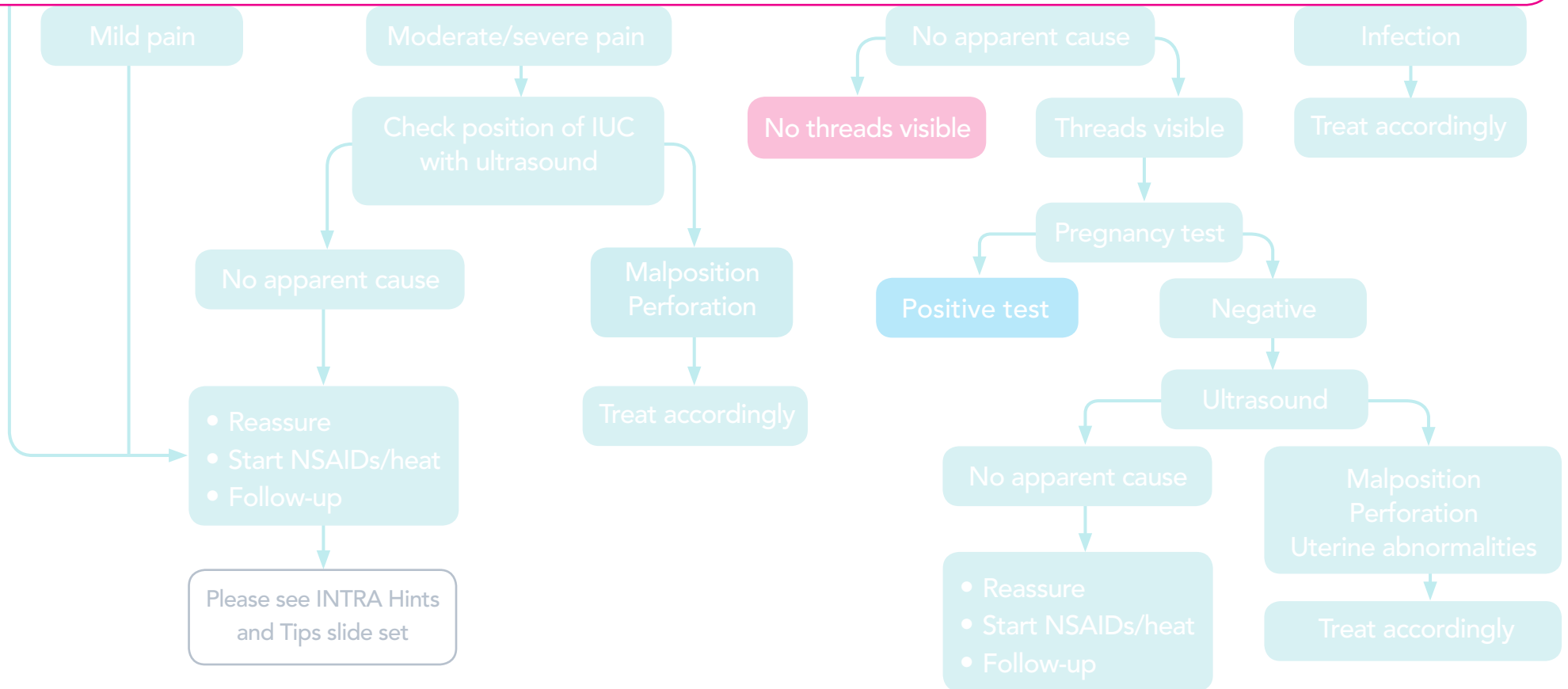


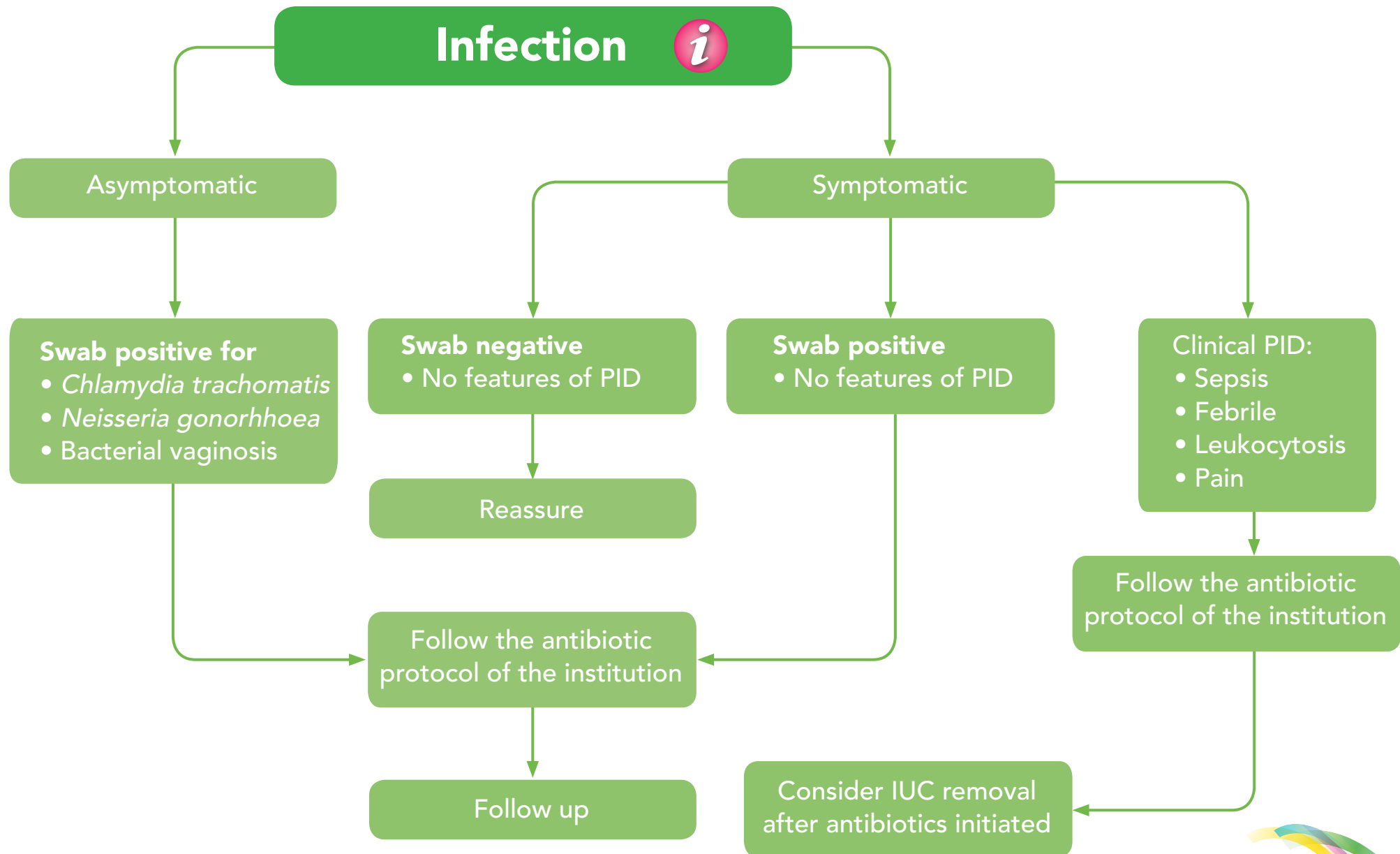




 **Additional information** CLOSE 

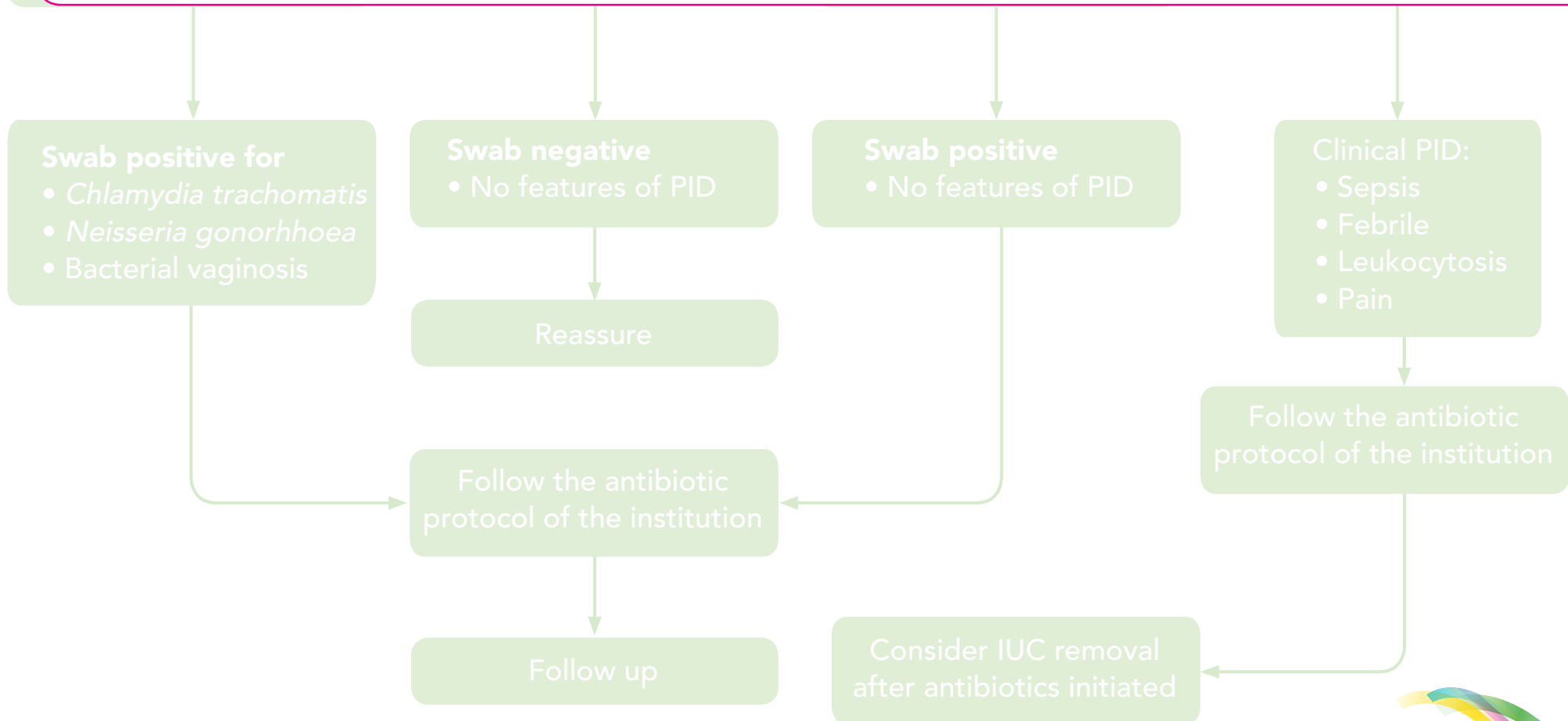
Amongst adolescent nulliparous and parous women, 20% experience no pain and 70% describe the pain as mild or moderate<sup>10</sup>





## Additional information CLOSE

Studies involving women of all ages, parity and risk of sexually transmitted infection (STI) show that the risk of pelvic inflammatory disease (PID) with IUC use is low (< 1%).<sup>7, 11-13</sup>



# Suspected perforation

Perforation with the sound

No IUC  
placement attempt

Conservative management  
and reassurance

Consider placement with  
ultrasound (in 2-3 weeks  
if patient still motivated  
to use IUC)

Perforation with the IUC

Strings visible:  
Remove immediately

Strings not visible:  
Confirm position with pelvic  
ultrasound or X-ray

Able to confirm position

Unable to confirm position

Carry out diagnostic hysteroscopy or  
diagnostic laparoscopy

Recommend surgical management

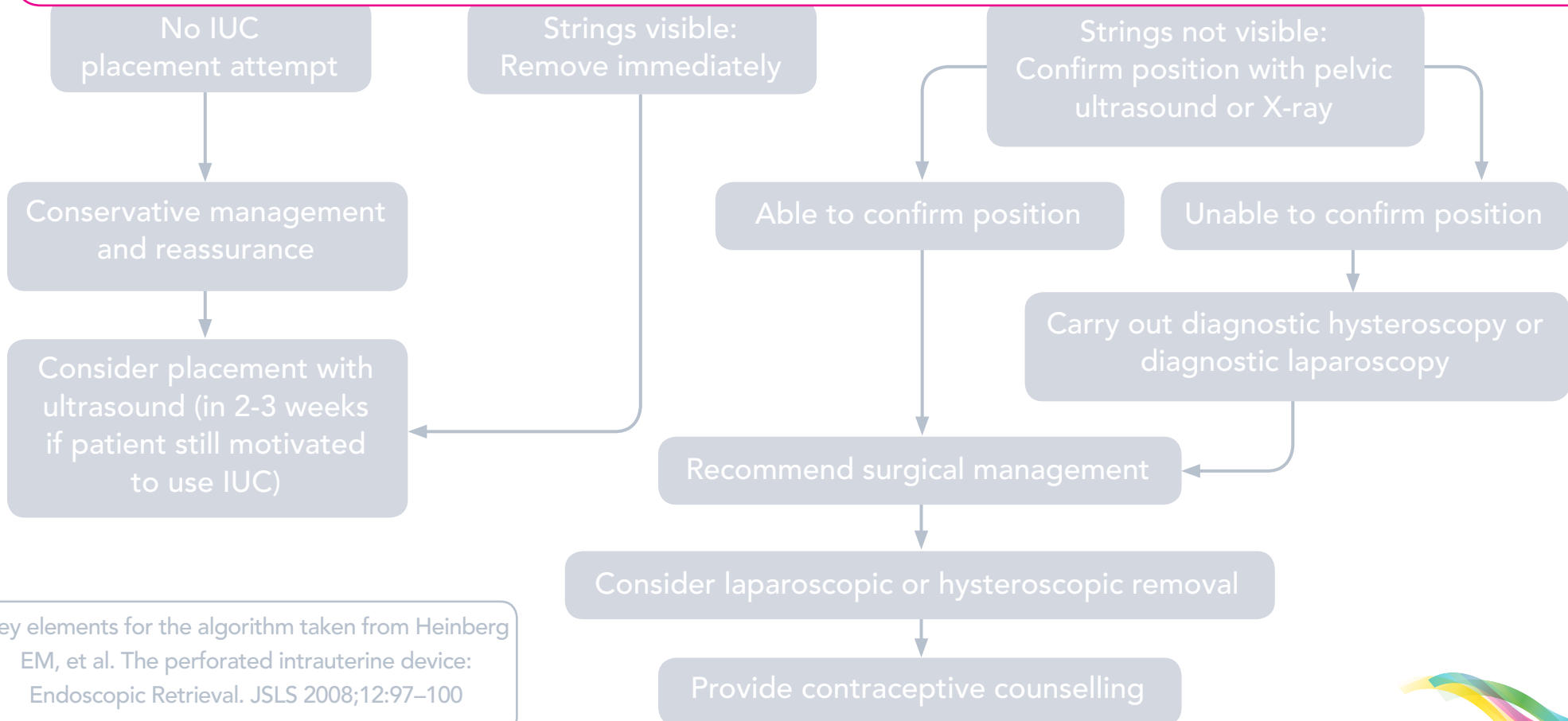
Consider laparoscopic or hysteroscopic removal

Provide contraceptive counselling

Key elements for the algorithm taken from Heinberg EM, et al. The perforated intrauterine device: Endoscopic Retrieval. JSL 2008;12:97-100

## Additional information CLOSE

EURAS-IUD shows a low risk of uterine perforation with IUC within the total patient population, incidence of perforation was ~1/1,000 placements.<sup>8</sup>



Key elements for the algorithm taken from Heinberg EM, et al. The perforated intrauterine device: Endoscopic Retrieval. JSL 2008;12:97-100

## References

1. Sedgh G, et al. Intended and unintended pregnancies worldwide in 2012 and recent trends. *Stud Fam Plann* 2014;45(3):301–314.
2. Trussell J. Contraceptive failure in the United States. *Contraception* 2011;83:397–404.
3. Heinemann K, et al. Comparative contraceptive effectiveness of levonorgestrel-releasing and copper intrauterine devices: the European Active Surveillance Study for Intrauterine Devices. *Contraception* 2015;91:280–283.
4. Marions L, et al. Use of the levonorgestrel releasing-intrauterine system in nulliparous women – a non-interventional study in Sweden. *Eur J Contracep Reprod Health Care* 2011;16:126–134.
5. Suhonen S, et al. Clinical performance of a levonorgestrel-releasing intrauterine system and oral contraceptives in young nulliparous women: a comparative study. *Contraception* 2004;69:407–412.
6. Bahamondes MV, et al. Ease of insertion and clinical performance of the levonorgestrel-releasing intrauterine system in nulligravidas. *Contraception* 2011;84:e11–16.
7. Gemzell-Danielsson K, et al. The effect of age, parity and body mass index on the efficacy, safety, placement and user satisfaction associated with two low-dose levonorgestrel intrauterine contraceptive systems; subgroup analysis of data from a phase III trial. *PLoS ONE* 2015;10(9):e0135309.
8. Heinemann K, et al. Risk of uterine perforation with levonorgestrel-releasing and copper intrauterine devices in the European Active Surveillance Study on Intrauterine Devices. *Contraception* 2015;91(4):274–279.
9. Black K, et al. A review of barriers and myths preventing the more widespread use of intrauterine contraception in nulliparous women. *Eur J Contracept Reprod Health Care* 2012;17:340–350.
10. Gemzell-Danielsson K, et al. A Phase III, single-arm study of LNG-IUS 8, a low-dose levonorgestrel intrauterine contraceptive system (total content 13.5 mg) in postmenarcheal adolescents. *Contraception* 2016 Feb 9. pii: S0010-7824(16)00036-6.
11. Farley TMM, et al. Intrauterine devices and pelvic inflammatory disease: an international perspective. *Lancet* 1992;339:785–788.
12. Sufrin CB, et al. Neisseria gonorrhea and Chlamydia trachomatis screening at intrauterine device insertion and pelvic inflammatory disease. *Obstet Gynecol* 2012;120(6):1314–1321.
13. Birgisson NE, et al. Positive Testing for Neisseria gonorrhea and Chlamydia trachomatis and the risk of pelvic inflammatory disease in IUD users. *J Womens Health (Larchmt)* 2015;24(5):354–359.